

# **Tracheal Collapse**

Robert Prošek, DVM, MS, DACVIM, DECVIM-CA

Veterinary Specialists Inc –Animal Heart Centers and University of Florida

## **What is the trachea?**

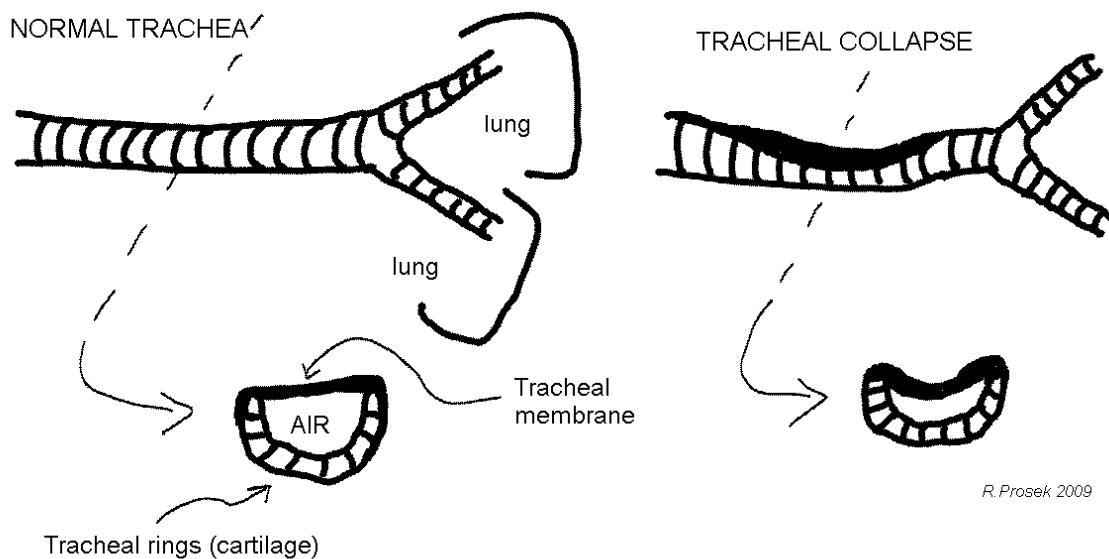
Trachea is the scientific name for windpipe, the tube that connects the nose, mouth, and throat to the lungs and serves as a conduit to bring air in and out of the lungs. The trachea is meant to be a fairly rigid tube consisting of smooth muscle connecting a group of cartilage rings. The rings are actually not complete circles; they are C-shaped and aligned in a row with the open end of the C facing upward toward the animal's neck and back. The muscle covering the open end of the C connecting the row of C-shaped rings together is called the tracheal membrane.

The trachea serves as a pipeline bringing air into and out of the chest. When an animal breathes, the trachea allows air to travel from the nose and mouth into the lungs and then back out again. The trachea extends from the throat to the middle part of the chest cavity. Thus, it is often referred to as having both an extrathoracic portion as well as an intrathoracic portion.

## **Why would a trachea collapse?**

Tracheas collapse because the cartilaginous C-shaped rings lose their strength and flatten. When the C-cartilage loses its curvature, the tracheal membrane across the ring gets loose and floppy. Instead of being a tight muscle covering, the membrane moves as air passes through the trachea. Two scenarios can occur. When air rushes into the chest during inhalation, the membrane of the intrathoracic trachea balloons outward and when air rushes out during exhalation, the membrane of the intrathoracic trachea droops down into the C-cartilage causing an occlusion. The tickling sensation and irritation of the membrane touching the tracheal lining stimulates a cough. If the obstruction interrupts breathing, the patient may become distressed, as they are having trouble getting enough oxygen to the deep parts of their lungs where the blood is oxygenated. If the collapse is in the extrathoracic (also called cervical) trachea, the opposite occurs; the membrane collapse takes place during inhalation and the ballooning during exhalation.

Panting or rapid breathing for any reason makes the collapse and anxiety worse, which unfortunately tends to generate more rapid breathing and a vicious cycle of distress. Making things worse still is the inflammation generated in the trachea. The collapse causes increased secretion and inflammation, thus promoting yet more coughing which subsequently leads to more inflammation. Ultimately, as the condition continues to progress and worsen, the tissues of the trachea undergo irreversible changes and lose their normal characteristics.



### What animals are affected?

The victim is almost always a toy- or small-breed dog. Yorkshire terriers, poodles, Chihuahuas, pugs, and Pomeranians are often thought of as the most commonly affected. Rarely, tracheal collapse occurs in larger breeds and even cats. The disease usually becomes problematic in middle age, but can occur at any age. The cartilage defect that leads to the flattened C rings appears to be hereditary.

Many dogs with collapsing tracheas do not ever develop clinical signs until a secondary problem complicates matters. Factors that enhance clinical signs often include:

- Obesity
- Anesthesia involving the placement of an endotracheal tube
- Development of kennel cough or other respiratory infection
- Increased respiratory irritants in the air (cigarette smoke, dust, etc.)
- Heart enlargement (causing compression on the trachea and mainstem bronchi)

If a secondary factor, such as one of those listed above, is making a previously incidental collapsing trachea a problem, often removal of the secondary factor (weight loss program, air filters – HEPA filters, etc.) may clear up the signs of the collapsed trachea.

### What is the treatment for tracheal collapse?

If any of the above listed secondary problems are a concern, they **MUST** be addressed. These problems will exacerbate the cough. Thus, none of the other treatments listed below will be successful without addressing these problems first.

Many animals with collapsing tracheas are unable to efficiently and effectively clear infectious organisms from the lower respiratory tract. Antibiotics may be indicated in these situations to clear up secondary infections.

Cough suppressants, such as hydrocodone, butorphanol, or diphenoxylate with atropine may work very well in some patients. However, it is important to make sure that a lower respiratory tract infection (i.e., pneumonia) is not present before instituting a cough suppressant.

Corticosteroids, such as prednisone, help minimize inflammation and mucous secretion, but are best used on a short term basis due to potential long-term side effects. Long term use may actually promote secondary infections and further weaken cartilage.

Bronchodilators, such as theophylline or terbutaline, are controversial as they may actually dilate the lower airways and not the trachea itself. However, by dilating lower airways, the pressure in the chest during inhalation decreases, which may therefore cause the trachea to collapse less.

### **Is tracheal collapse an emergency?**

In occasional situations, the collapsing tracheal membrane becomes so obstructive and the patient gets so distressed that adequate oxygen exchange cannot occur. The patient's normal pink gum and tongue color may become blue-tinged, and the patient may even faint or collapse to the ground. If the patient reaches the point where distress seems extreme or if collapse results, treat this as an emergency and rush the pet to emergency veterinary care. The veterinarian may use tranquilization to help relieve the anxiety that perpetuates the heavy breathing and coughing. Oxygen therapy and cough suppressants may also be beneficial.

### **Are there any surgical options for tracheal collapse?**

If medical management does not produce satisfactory results, surgery may be used as a last resort. Several surgical techniques currently exist which are designed to strengthen the trachea from either outside or inside the airway to help prevent it from collapsing. Some techniques require a rigid prosthesis to be placed and bonded around the trachea effectively creating a non-collapsible tube. The newest technique uses a self-expanding stainless steel prosthesis which is applied inside the lumen of the trachea. Despite what technique is used, surgery is largely effective as long as the portion of trachea that is collapsed is external to the chest. Should the intrathoracic trachea or mainstem bronchi be involved, surgery becomes far less successful.

### **Is tracheal collapse associated with liver disease?**

In a 2006 issue of the *Journal of the American College of Veterinary Internal Medicine*, a group of researchers led by Bauer pursued the common finding of enlarged liver in dogs with tracheal collapse. Her group looked at 26 dogs with tracheal collapse and compared

liver function test results to 42 dogs without tracheal collapse. Ninety-two percent (92%) of dogs with tracheal collapse were found to have abnormal results. Dogs that received stent placement to assist their breathing showed improvement in these tests. It was concluded that oxygen deprivation from the collapse had resulted in significant liver disease in many tracheal collapse patients. It was further recommended that tracheal collapse patients have liver function tests evaluated as liver supportive medications may be helpful.